

# Comparison between axillary hair removal with a continuously scanned Diode laser and a spot-to-spot scanned Alexandrite Laser (EpiCon-Study)

Bodendorf Marc Oliver<sup>1</sup>, Grunewald Sonja<sup>1</sup>, Preuss Madeleine<sup>2</sup>, Simon Jan-Christoph<sup>1</sup>, Paasch Uwe<sup>1</sup>

<sup>1</sup>Department of Dermatology, Venerology and Allergology, University of Leipzig, Germany

<sup>2</sup>University of Applied Sciences (Hochschule für Technik, Wirtschaft und Kultur) Leipzig, Germany

## Background:

With an increasing request for permanent removal of unwanted hair, new devices are generated in order to increase quality and efficacy of laser epilation. As especially larger areas (legs, back, chest) reach the focus of interest, these devices should fulfill a demand for extensive spot-sizes. In consequence, this led to the creation of scanned laser systems. A new continuously scanned diode laser has been shown to be superior over a point-to-point arrangement in mathematical models regarding efficacy of energy application.

## Objective

In order to compare the in-vivo-effects of a continuously scanned Diode laser (808 nm) and a spot-to-spot scanned Alexandrite Laser (755 nm), we conducted a clinical trial on the removal of axillary hair (EpiCon-Study).

## Methods Materials

31 Patients (28 female, 3 male) were treated 6 times in the right axilla with a spot-by-spot scanned alexandrite Laser ("Arion", 755 nm, Quantel Derma, Germany) and in the left axilla with a continuously scanned diode laser ("Leda", 808 nm, Quantel Derma, Germany, for more details see Appendix - **Graph 1**). An additional air cooling was conducted. Before therapy and before each treatment, lens-enlarged photographs of the treated area were taken with a dermoscope (Trichoscan<sup>®</sup>, Foto Finder Systems GmbH, Germany) and hair reduction was documented (see also Appendix - **Graph 2**). Patients filled in a questionnaire regarding convenience of both laser systems. Additionally, physicians evaluated redness and perifollicular edema post therapy and treatment time was measured.

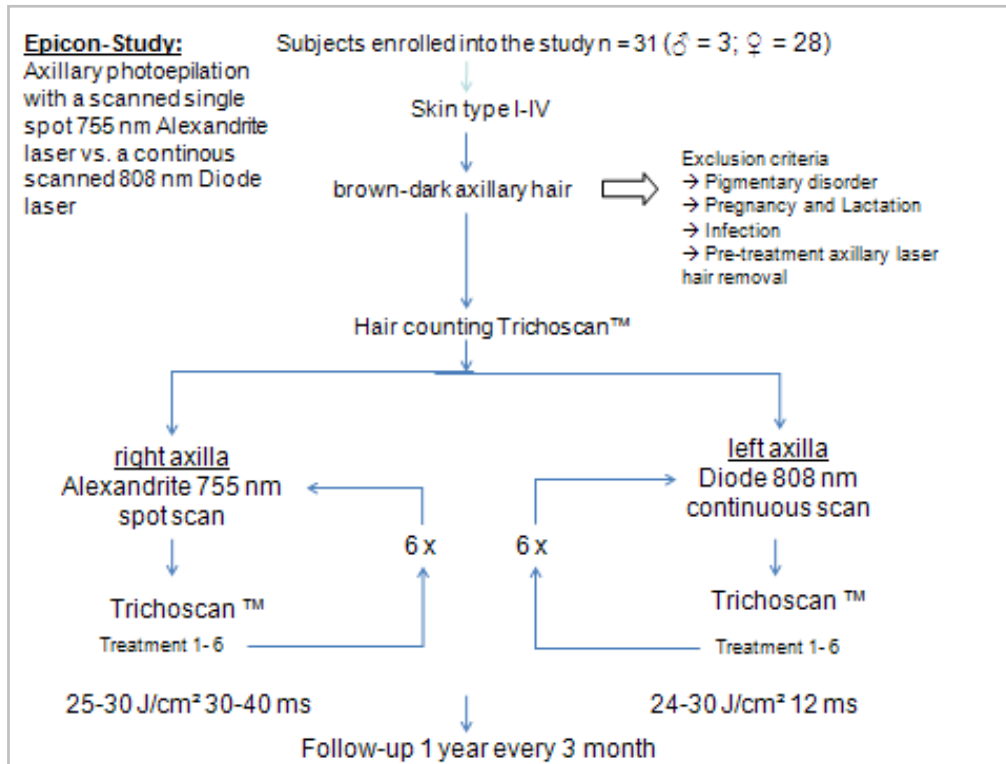
**Results:**

Both systems showed a comparable, significant hair reduction (see Appendix - **Graph 3**). Differences in hair reduction between both systems were statistically not significant, whereas differences concerning side effects were statistically significant: When conducting comparable energies, the continuously scanned diode laser produced less perifollicular edema and redness (see Appendix - **Graph 3**). Furthermore, the intensity of pain was evaluated worse with the diode laser by 62% of the patients. But with an average treatment time of approximately one fifth of alexandrite treatment, the inconvenience lasted much shorter. Pain levels of both laser systems were rated acceptable by all patients (see Appendix -**Graph 3**).

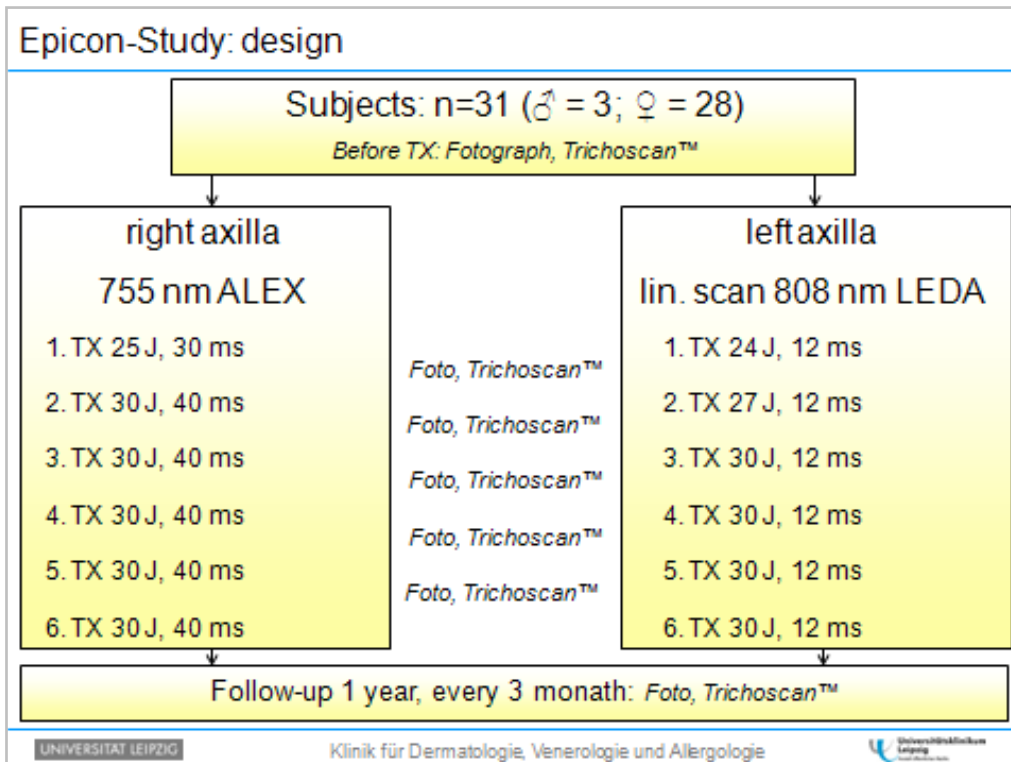
**Conclusions:**

The continuously scanned diode laser system shows comparable results to a spot-to-spot scanned alexandrite laser when removing unwanted axillary hair. The treatment could be conducted much faster and side effects were rated significantly lower. Discomfort was rated acceptable by all of the patients.

Clinical Study -



Graph 1: Epicon-study strategy



Graph 2: Epicon-Study design


**Effectiveness**

**Results: Trichoscan (haircount per 0.651 cm<sup>2</sup>)**

Breakdown table of descriptive statistics

Smallest n for any variable: 187

Timepoint	Leda - n	Leda Means ± SD	Alex - n	Alex Means ± SD
Before Tx1	39	20 ± 7.3	40	21 ± 6.2
Before Tx2	31	13 ± 5.8	31	13 ± 5.5
Before Tx3	32	11 ± 7.4	32	12 ± 6.8
Before Tx4	29	10 ± 4.2	29	9 ± 4.3
Before Tx5	29	9 ± 5.8	29	9 ± 7.7
Before Tx6	27	6 ± 3.1	27	7 ± 3.8

UNIVERSITÄT LEIPZIG      Klinik für Dermatologie, Venerologie und Allergologie      

**Graph 3:** Results of the Trichoscan after 5 treatments. The Trichoscan was performed directly before each session.

There are no significant differences in the effectiveness between LEDA Epi and ARION. But the parameter range was limited with the prototype of the LEDA Epi (21 – 30 J/cm<sup>2</sup>, 12 ms). Therefore no optimization was performed but the results were pretty good.

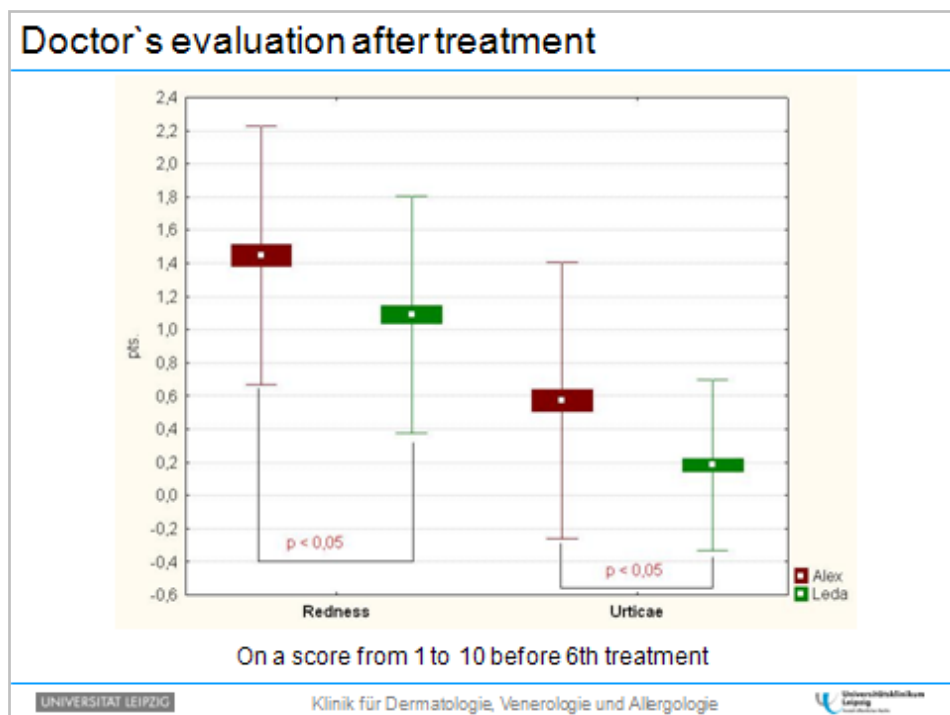
Side effects

Patients' evaluation one hour after treatment

	Alexandrit	LEDA
Efficacy & Speed	very high	very high
Side effects		
Redness / Urticaria	little	very little
Pruritus	marginal	marginal
Crust	< 2% (2/120)	none
Scarring	none	none
Physical restraint	none	none

UNIVERSITÄT LEIPZIG Klinik für Dermatologie, Venerologie und Allergologie

Graph 4: Patients' evaluation 1 hour after treatment



Graph 5: Doctor's evaluation after treatment

Treatments with the LEDA Epi show definitely less side effects than treatments with the ARION. Redness is reduced by 30% and urticae (blister formation) even by 60%. The patients rated the pain score medium (<6 on a score from 1 – 10).

**Treatment time**

Significant reduction of treatment time using LEDA

Localization	Treatment time
Upper lip	app. 4-5 s
Axilla	app. 15-20 s
Cheeks, chin and upper lip	app. 1-2 min
Leg complete	app. 7-8 min
Back	app. 8-10 min

UNIVERSITÄT LEIPZIG
Klinik für Dermatologie, Venerologie und Allergologie
Universitätsklinikum  
Leipzig

**Graph 6:** List of treatment times with the LEDA Epi 808 at different locations